

Case report

Open Access

Colonic perforation following mild abdominal trauma in a patient with Crohn's disease: a case report

John Bunni*, Simon JW Monkhouse and Christopher P Armstrong

Address: Department of Upper GI Surgery, Frenchay Hospital, Bristol, UK

Email: John Bunni* - johnbunni@hotmail.com; Simon JW Monkhouse - sjwmonkhouse@hotmail.com;

Christopher P Armstrong - Kit.Armstrong@nbt.nhs.uk

* Corresponding author

Published: 19 March 2008

Received: 4 February 2008

World Journal of Emergency Surgery 2008, 3:13 doi:10.1186/1749-7922-3-13

Accepted: 19 March 2008

This article is available from: <http://www.wjes.org/content/3/1/13>

© 2008 Bunni et al; licensee BioMed Central Ltd.

This is an Open Access article distributed under the terms of the Creative Commons Attribution License (<http://creativecommons.org/licenses/by/2.0>), which permits unrestricted use, distribution, and reproduction in any medium, provided the original work is properly cited.

Abstract

Colonic perforation following mild abdominal trauma in patients with Crohn's disease is a rare occurrence. We present a case of a 21 year old Crohn's sufferer, who presented to the emergency department with signs of shock and peritonitis following minor abdominal trauma. A computed tomography (CT) scan revealed ascending colonic perforation and he underwent a subsequent right hemicolectomy. This is the first UK report of a patient with inflammatory bowel disease suffering colonic perforation following minimal trauma.

Background

Inflammatory bowel disease is not uncommonly encountered by the general surgeon. Surgeons are normally asked for input in patients who have failed medical therapy or are suffering with complications of the disease, such as fistulation, toxic megacolon or abscess formation.

Perforation is unusual in Crohn's patients, with a reported incidence of 1–2% during the course of the illness [1]. It is thought this may be due to the chronic inflammatory nature of the condition with fibrosing strictures being the more usual presentation.

Perforation of the colon during colonoscopy is well recognised in patients with inflammatory bowel disease, yet there is very little in the literature on colonic perforation after minimal abdominal trauma. Literature review revealed only one such case in the United States [2].

Case presentation

A 21 year old male presented to the emergency department with severe acute abdominal pain. He had been

playing football earlier and was struck in the abdomen by an opponents shoulder. At the time, the impact was considered to be trivial. Subsequently, he developed abdominal pain and was brought to hospital. He had a history of Crohn's disease and was being managed by the gastroenterologists as an out patient. A Barium enema several months previously had shown evidence of Crohn's disease in the terminal ileum and ascending colon. He had no previous surgery and was not on steroids at the time.

On examination he was hypotensive and tachycardic. His abdomen displayed signs of generalised peritonitis.

Blood test showed mildly raised inflammatory markers and an erect chest x-ray showed no convincing evidence of pneumoperitoneum. The patient was fluid resuscitated and given he was haemodynamically stable; a CT was performed to diagnose further prior to surgery. Clinically, a splenic injury was the working diagnosis. Computed tomography scan revealed free gas and a perforation of the ascending colon (fig 1). There was no evidence of splenic

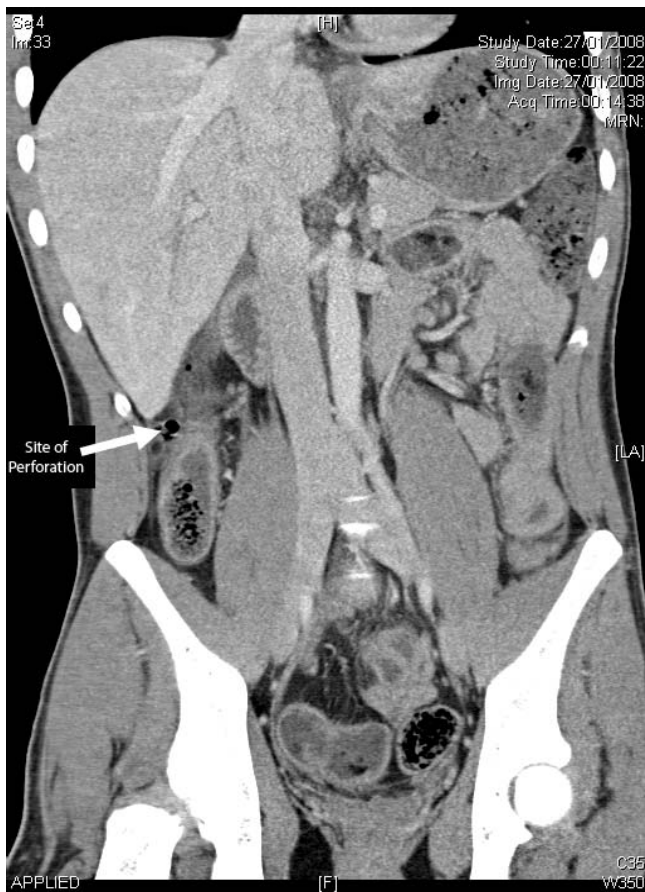


Figure 1
Computed tomography image of ascending colon perforation – coronal view.

laceration or subcapsular haematoma of the liver. He proceeded to laparotomy.

There was evidence of Crohn's disease involving the distal 10 cm of small bowel and right colon up to one third the way of the transverse colon. 2 perforations were evident in the ascending colon, which was thickened. There were no apparent strictures distal to the perforation that could have resulted in a distended area of bowel that ruptured. A right hemicolectomy and primary anastomosis was performed. The resection involved 10 cm of terminal ileum, which corresponded to the diseased segment of small bowel as shown on the barium study done previously. Histology of the specimen confirmed macroscopic and microscopic features of Crohn's disease. Unfortunately, the patient developed a post-operative wound infection that resulted in a return visit to theatre for a wash-out, but remained stable.

Conclusion

In patients with underlying Crohn's disease and evidence of peritonitis, we propose a low threshold for CT imaging, even if the erect chest radiograph appears normal. It appears that the underlying inflammation and oedema can make the bowel more prone to perforation in the event of trauma, however minimal it may be. The combination of friable colonic wall, the possibility of steroid use and the relative young age of this patient group makes clinical diagnosis more difficult. Clinicians need to bear in mind the possibility of perforation as signs may be subtle.

Authors' contributions

All authors were responsible for the surgery. CPA was responsible for the ongoing care of the patient in hospital. JB, SJWM and CPA conceived of the case report. JB researched and drafted the manuscript. All authors read and approved the final manuscript.

Acknowledgements

The patient kindly gave full written permission for this report to be made including the use of computed tomography images.

References

1. Roy MK, Delicata RJ, Carey PD: **Crohn's disease presenting with acute colonic perforation.** *Postgrad Med J* 1997, **73(864)**:645-6.
2. Johnson GA, Baker J: **Colonic perforation following mild trauma in a patient with Crohn's disease.** *Am J Emerg Med* 1990, **8(4)**:340-1.

Publish with **BioMed Central** and every scientist can read your work free of charge

"BioMed Central will be the most significant development for disseminating the results of biomedical research in our lifetime."

Sir Paul Nurse, Cancer Research UK

Your research papers will be:

- available free of charge to the entire biomedical community
- peer reviewed and published immediately upon acceptance
- cited in PubMed and archived on PubMed Central
- yours — you keep the copyright

Submit your manuscript here:
http://www.biomedcentral.com/info/publishing_adv.asp

